

CUTANEOUS
MEDICINE
FOR THE
PRACTITIONER

VOL. 84 NO. 3

SEPTEMBER 2009

cutis®

Featuring

Serum Interferon- γ Is a
Psoriasis Severity and
Prognostic Marker

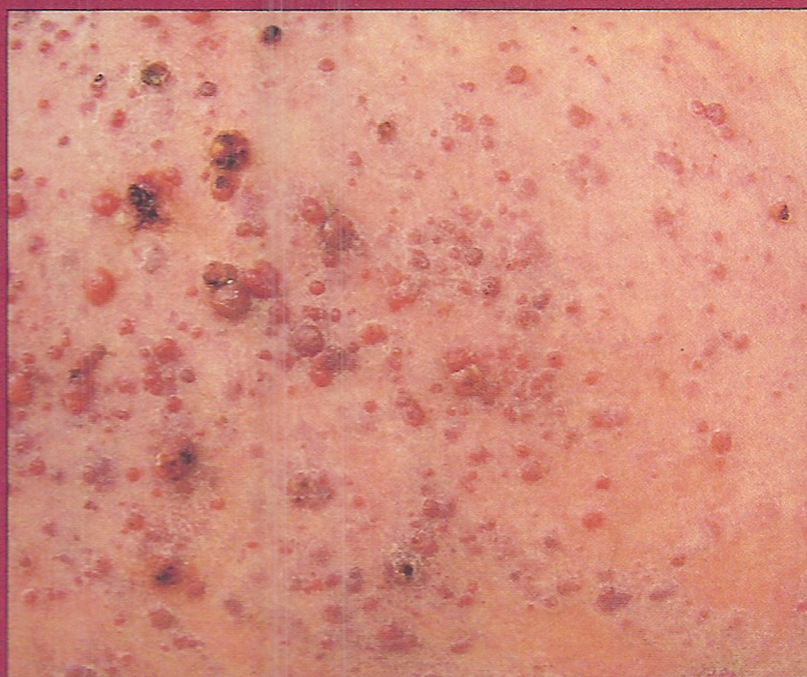Skin Biopsies to Assess
Response to Systemic
Corticosteroid Therapy
in Early-Stage TEN

Tinea Cruris in Children

CME

In-Transit Metastasis
From Melanoma Presenting
as Lymphangiectasis

Pili Torti



FOCUS ON PSORIASIS

#BXNPKPK *****RUT0**SCH 5-DIGIT 34231
#9060 2660 602# U 05/08 AM 09CT
SEA CUT 1 SEP09 0014 #59 #8641
J MORGAN O-DONOGHUE - DERMATOLOGIST
ADVANCES IN DERMATOLOGY
1952 FIELD RD STE B1
SARASOTA FL 34231-2342

Complete contents inside

Skin Biopsies to Assess Response to Systemic Corticosteroid Therapy in Early-Stage TEN: Case Report and Review of the Literature

J Morgan O'Donoghue, MD; Yvana P. Céspedes, MD; Paul F. Rockley, MD; Thomas P. Nigra, MD

Toxic epidermal necrolysis (TEN) is a severe, mucocutaneous, necrolytic reaction to a variety of antigenic stimuli. The use of systemic corticosteroids in the treatment of TEN is controversial because of a lack of randomized, controlled, prospective studies, and because the effects of steroid therapy vary depending on the dosage and time of its administration during the course of TEN. Immediate intervention is crucial, and the response to corticosteroids in early-stage TEN can be difficult to clinically assess. In this report, we describe the use of serial skin biopsies to determine the efficacy of high-dose corticosteroids in patients with early-stage TEN. We present the case of a woman who was started on antiepileptic therapy with phenytoin sodium and developed TEN shortly thereafter. She was treated with intravenous methylprednisolone acetate for 1 week. The progression of the skin eruption was halted and the patient's condition began to stabilize. Skin biopsy specimens taken before and after steroid therapy revealed substantial improvement of the lymphocytic infiltrate and arrested epidermal necrosis. Serial skin biopsies in patients with early-stage TEN are helpful in assessing the initial response to corticosteroids and thus guide further therapy.

Cutis. 2009;84:138-140,161-162.

From the Departments of Pathology and Dermatology, Washington Hospital Center, Washington, DC.

The authors report no conflict of interest.

Correspondence: J Morgan O'Donoghue, MD, O'Donoghue Dermatology, 1952 Field Rd, Sarasota, FL 34231 (dermatologyexperts@yahoo.com).

Case Report

A 26-year-old woman with a medical history of systemic lupus erythematosus and vasculitis developed grand mal seizures, which were controlled with oral phenytoin sodium 300 mg daily. Three weeks later, she noticed the onset of generalized pruritus and skin tenderness. The following day, she developed fever; chills; mucous membrane swelling; and a symmetrical, erythematous, morbilliform eruption on the extensor aspects of the distal extremities. In the next 24 hours, the eruption slowly evolved from discrete reddish macules and papules to confluent necrotic blisters involving the extremities, trunk, head, neck, and mucosal surfaces.

At the time of examination, the patient had a fever of 40°C, widespread tender erythema, hemorrhagic vesiculobullous lesions, and seropurulent crusted erosions. Approximately 20% of the body surface area (BSA) was covered with necrotic epidermis. A positive direct Nikolsky sign was noted on lesional skin only. Mucosal surfaces contained some inflammatory bullous and erosive lesions. Conjunctival involvement was characterized by bilateral chemosis, redness, and lacrimation.

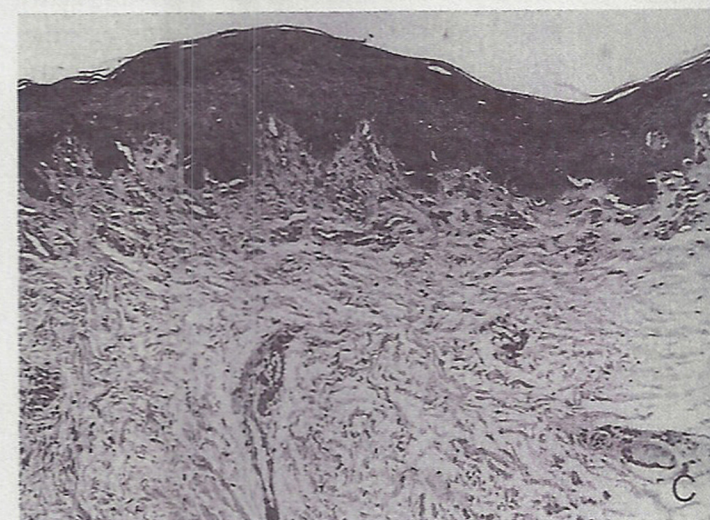
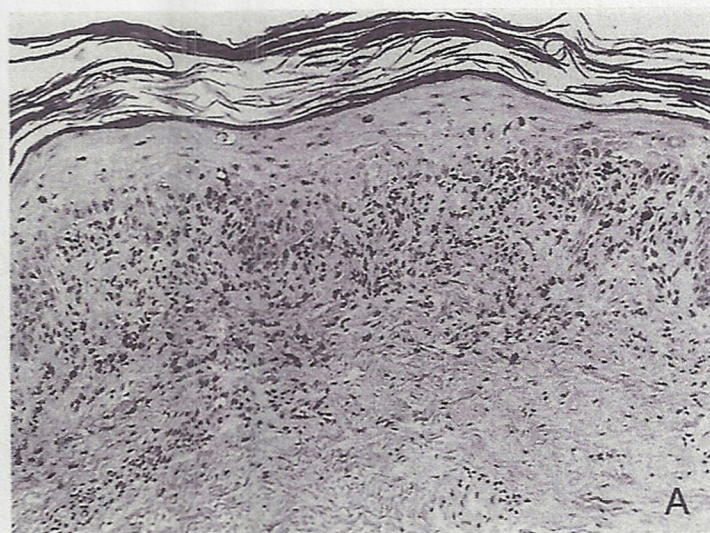Laboratory studies revealed the following levels: white blood cell count, $6.0 \times 10^3/\mu\text{L}$ (reference range, $4.5\text{--}11.0 \times 10^3/\mu\text{L}$) with 34% lymphocytes, 32% bands, 17% monocytes, 9% granulocytes, and 8% metamyelocytes; erythrocyte count, $3.12 \times 10^6/\mu\text{L}$ (reference range, $4.5\text{--}5.9 \times 10^6/\mu\text{L}$); hemoglobin, 9.0 g/dL (reference range, 14.0–17.5 g/dL); hematocrit, 26.6% (reference range, 35%–45%); and platelet count, $162 \times 10^3/\mu\text{L}$ (reference range, $150\text{--}400 \times 10^3/\mu\text{L}$). Serum chemistries were remarkable for the following: serum urea nitrogen, 28 mg/dL (reference range, 8–23 mg/dL);

creatinine, 1.5 mg/dL (reference range, 0.6–1.2 mg/dL); glucose, 160 mg/dL (reference range, 70–110 mg/dL); total protein, 4.0 g/dL (reference range, 6.0–8.0 g/dL); albumin, 1.6 g/dL (reference range, 3.5–5.0 g/dL); and lactate dehydrogenase, 278 U/L (reference range, 100–200 U/L). Results of liver function tests and coagulation studies were within reference range. Chest x-rays were normal. Urinalysis demonstrated a total protein level of 20 g/dL, 20 to 50 red blood cells per high-power field (HPF), 3 to 6 white blood cells per HPF, 20 to 50 granular casts per HPF, and 2 or more bacteria per HPF. Blood cultures grew coagulase-negative staphylococci and beta-hemolytic streptococci.

A skin biopsy specimen from intact erythematous abdominal skin revealed slight spongiosis; scattered necrotic keratinocytes; vacuolar degeneration of the basal layer; focal cleft formation at the dermoepidermal junction; and a moderate lymphohistiocytic infiltrate at the dermoepidermal junction and around superficial dermal blood vessels (Figure, A). These histologic findings are characteristic of toxic epidermal necrolysis (TEN). The clinical diagnosis of TEN was suggested by the skin biopsy results. Phenytoin sodium was implicated as the cause because of the temporal relationship between starting the drug and the development of TEN; therefore, it was discontinued.

The patient was treated with one dose of intravenous methylprednisolone acetate 100 mg (2 mg/kg), followed by 50 mg (1 mg/kg) every 8 hours for 3 days. She also received intravenous fluids, antibiotics, antipyretics, analgesics, and blood transfusions. Topical therapy consisted of viscous lidocaine hydrochloride; colloidal oatmeal soaks; dressing exfoliated areas with mupirocin cream and petrolatum covered with gauze; and ophthalmic application of lubricants, antibiotic ointment, and prednisolone eye drops.

At the end of the third hospital day, the patient was afebrile, the eruption was less erythematous, there were no new areas of necrolysis, and the patient's condition stabilized. A follow-up biopsy specimen from abdominal skin after 3 days of therapy showed a reduction of the lymphohistiocytic infiltrate without evidence of progressed keratinocyte necrosis (Figure, B). Methylprednisolone acetate was switched to hydrocortisone acetate at physiologic (stress) doses. In the next few days, sloughed areas began to reepithelialize. A third abdominal skin biopsy specimen obtained after 1 week of therapy revealed further reduction of the lymphohistiocytic infiltrate (Figure, C). Results from repeat laboratory studies revealed that neutropenia resolved, serum urea nitrogen and creatinine levels were within reference range, urinalysis



This series of photomicrographs illustrates the progressive decrease in lymphocytic inflammation during the administration of systemic corticosteroids in a patient with toxic epidermal necrolysis. Before treatment, numerous lymphocytes are present in the upper dermis with extension into the epidermis and numerous dyskeratotic epidermal cells (A). Reduction of lymphohistiocytic infiltrate of the dermis and epidermis after 3 days of systemic corticosteroid administration (B). Inflammation is absent and epidermal necrosis is largely resolved after 1 week of therapy. Melanophages are present in the upper dermis (C) (all H&E, original magnification $\times 120$).

returned to baseline, and blood cultures were negative for bacterial growth. Corticosteroids were tapered to 5 mg daily, and she was discharged in good condition after 4 weeks of hospitalization. On follow-up cutaneous examination, postinflammatory pigmentary changes were noted, but there were no substantial sequelae from mucosal scarring.

Comment

In 1956, Lyell¹ and Lang and Walker² independently described TEN. Lyell¹ coined the term "toxic epidermal necrolysis," referring to epidermal damage caused by a presumed circulating toxin. Patients with brain tumors, systemic lupus erythematosus, or human immunodeficiency virus infection, or bone marrow transplant recipients are at increased risk for the development of TEN.³ Currently, TEN is viewed as a mucocutaneous reaction to a variety of antigenic stimuli,⁴ including drugs, infections, collagen-vascular disease, malignancy, pregnancy, menstruation, and vaccination. The most commonly implicated medications are allopurinol, antibiotics, barbiturates, carbamazepine, hydantoin, nonsteroidal anti-inflammatory drugs, and sulfonamides,⁵ which are typically initiated 1 to 3 weeks prior to the onset of TEN. In our patient, the delay between the introduction of phenytoin sodium and the onset of TEN may be attributed to long-term steroid therapy.⁶

The pathophysiologic events involved in TEN are not completely understood. Proposed pathogenic mechanisms include type IV hypersensitivity reactions (delayed hypersensitivity and lymphocyte-mediated cytotoxicity), type II cytotoxic reactions, and altered metabolism of the offending drug. In some cases of TEN, positive patch and lymphocyte transformation tests have been used to support the delayed hypersensitivity hypothesis.⁷ Immunohistologic studies stress the importance of cell-mediated cytotoxicity in which a helper T cell (T_H1)-like cytokine response may direct the traffic of effector CD8 T lymphocytes⁸ and/or macrophages into the epidermis, causing keratinocyte damage in a process referred to as satellite cell necrosis.⁹ These findings are similar to skin graft rejection or graft-vs-host disease in which CD8 T lymphocytes and macrophages are the effector cells of an acute cell-mediated reaction against allogeneic antigens. Animal models¹⁰ and human data¹¹ suggest that acute graft-vs-host disease and TEN share several biologic, immunologic, clinical, and histologic features. In support of a role for type II cytotoxic reactions in patients with drug-induced TEN, indirect immunofluorescence studies and complement-dependent cytotoxicity assays have demonstrated common antigenic

determinants on keratinocytes and monocytes that may serve as targets for drug-induced antibodies.⁵ In addition, impaired metabolism of an offending drug can produce reactive metabolites that may act as haptens by binding to keratinocyte surface proteins, thus generating an immune response.¹² It is theorized that an apoptotic mechanism could account for the generalized cell death created in TEN.¹³ Further studies are needed to determine which of these pathogenic mechanisms is the predominant cause of necrolysis.

The use of systemic corticosteroids in the treatment of TEN is controversial because of a lack of randomized, controlled, prospective studies, and because the effects of steroid therapy vary depending on the dosage and time of its administration during the course of TEN. In patients presenting with early-stage TEN (erythrodermic, slowly evolving cases with <25% total BSA necrolysis), proponents of steroids recommend the administration of high-dose methylprednisolone acetate (1–3 mg/kg daily) to limit epidermal sloughing and occasionally arrest progression of disease.^{14–18} One study indicates that TEN can occur in some patients undergoing long-term steroid therapy for underlying disease; however, most of these patients were on low-dose regimens.⁶ Although the mechanism of action of high-dose corticosteroids in TEN remains unknown, the rationale for their use is based upon the theories that some cases of TEN are due to delayed hypersensitivity reactions or lymphocyte-mediated cytotoxic reactions.⁴ These immunopathogenic mechanisms are mediated by T lymphocytes. Our patient's clinical improvement correlated with the administration of high-dose systemic corticosteroids and the progressive reduction of the lymphohistiocytic infiltrate.

In patients presenting with late-stage disease (rapidly evolving cases with >25% total BSA necrolysis), the risks associated with using steroids, regardless of the dosage, outweigh their benefits.^{19,20} Many of the reports ascribing negative outcomes to the administration of steroids involved patients with late-stage disease.^{21–23} Because the majority of patients with TEN have late-stage disease when they receive medical attention, most patients should not be treated with systemic corticosteroids. Patients with late-stage TEN should be managed in burn centers with vigorous fluid resuscitation, topical antimicrobial agents, biologic dressings, debridement, wound care, nutritional support, and physical and psychological therapy protocols.²⁴ Adjunctive therapies include hyperbaric oxygen^{2,25} and plasmapheresis.²⁶

CONTINUED ON PAGE 161

CONTINUED FROM PAGE 140

This case demonstrates that serial skin biopsies in patients with early-stage TEN may be useful to assess the response to corticosteroids, guide therapy, and minimize potential complications. These biopsies can be particularly helpful in managing patients at high risk for infection, such as those patients with neutropenia. Because inflammatory infiltrates can occur in response to necrolysis, it is important to obtain all biopsies from intact, erythematous, nonnecrotic skin sites with similar clinical appearance. If a follow-up biopsy after 48 to 72 hours of high-dose corticosteroids shows a good response of decreasing the lymphohistiocytic infiltrate and halting epidermal necrosis, then corticosteroids can be tapered cautiously over 1 to 3 weeks. Relapses have been reported following rapid withdrawal of corticosteroids.^{17,27-29} Patients with biopsies revealing a partial response may benefit from an additional 48 hours of therapy; however, high-dose corticosteroids are not recommended for more than a total duration of 5 days.³⁰ If a follow-up biopsy shows progression of either the infiltrate or epidermal necrosis, corticosteroids should be abruptly discontinued unless they are unequivocally indicated for a coexisting condition. Partial responders and nonresponders can be treated with other immunosuppressive agents, including azathioprine 2 to 3 mg/kg daily,²⁷ intravenous cyclophosphamide 100 to 300 mg daily,³¹ or oral cyclosporine 3 to 4 mg/kg daily.³² Cyclophosphamide and cyclosporine inhibit proliferation of T lymphocytes in patients with TEN.^{31,32} These agents may be effective as monotherapy in steroid-resistant cases or have additive/synergistic effects in combination with steroids. Further studies assessing the clinical and histopathologic response of early-stage TEN to immunosuppressive therapy are needed to establish treatment guidelines.

REFERENCES

1. Lyell A. Toxic epidermal necrolysis: an eruption resembling scalding of the skin. *Br J Dermatol.* 1956;68:355-361.
2. Lang R, Walker J. An unusual bullous eruption. *S Afr Med J.* 1956;30:97-98.
3. Bourgault-Villada I, Roujeau J-C. Toxic epidermal necrolysis. *Curr Prob Dermatol.* 1996;3:99-104.
4. Parsons JM. Toxic epidermal necrolysis. *Int J Dermatol.* 1992;31:749-768.
5. Wolkenstein PE, Roujeau JC, Revuz J. Drug-induced toxic epidermal necrolysis. *Clin Dermatol.* 1998;16:399-408.
6. Guibal F, Bastuji-Garin S, Chosidow O, et al. Characteristics of toxic epidermal necrolysis in patients undergoing long-term corticosteroid therapy. *Arch Dermatol.* 1995;131:669-672.
7. Tagami H, Tatsuta K, Iwatsuki K, et al. Delayed hypersensitivity in ampicillin-induced toxic epidermal necrolysis. *Arch Dermatol.* 1983;119:910-913.
8. Correia O, Delgado L, Ramos JP, et al. Cutaneous T-cell recruitment in toxic epidermal necrolysis. *Arch Dermatol.* 1993;129:466-468.
9. Paquet P, Piérard GE. Erythema multiforme and toxic epidermal necrolysis: a comparative study. *Am J Dermatopathol.* 1997;19:127-132.
10. Merot Y, Saurat JH. Clues to pathogenesis of toxic epidermal necrolysis. *Int J Dermatol.* 1985;24:165-168.
11. Takeda H, Mitsuhashi Y, Kondo S, et al. Toxic epidermal necrolysis possibly linked to hyperacute graft-versus-host disease after allogeneic bone marrow transplantation. *J Dermatol.* 1997;24:635-641.
12. Friedmann PS, Strickland I, Pirmohamed M, et al. Investigation of mechanisms in toxic epidermal necrolysis induced by carbamazepine. *Arch Dermatol.* 1994;130:598-604.
13. Sugimoto Y, Mizutani H, Sato T, et al. Toxic epidermal necrolysis with severe gastrointestinal mucosal cell death: a patient who excreted long tubes of dead intestinal epithelium. *J Dermatol.* 1998;25:533-538.
14. Björnberg A. Fifteen cases of toxic epidermal necrolysis (Lyell). *Acta Derm Venereol.* 1973;53:149-152.
15. Parsons JM. Management of toxic epidermal necrolysis. *Cutis.* 1985;36:305-307, 310-311.
16. Sherertz EF, Jegasothy BV, Lazarus GS. Phenytoin hypersensitivity reaction presenting with toxic epidermal necrolysis and severe hepatitis. *J Am Acad Dermatol.* 1985;12:178-181.
17. Tegelberg-Stassen MJ, van Vloten WA, Baart de la Faille H. Management of non-staphylococcal toxic epidermal necrolysis: follow-up study of 16 case histories. *Dermatologica.* 1990;180:124-129.
18. Stables GI, Lever RS. Toxic epidermal necrolysis and systemic corticosteroids [letter]. *Br J Dermatol.* 1993;128:357.
19. Revuz J, Roujeau J-C, Guillaume J-C, et al. Treatment of toxic epidermal necrolysis. Créteil's experience. *Arch Dermatol.* 1987;123:1156-1158.
20. Herndon DN. Toxic epidermal necrolysis: a systemic and dermatologic disorder best treated with standard treatment protocols in burn intensive care units without the prolonged use of corticosteroids. *J Am Coll Surg.* 1995;180:340-342.
21. Halebian PH, Corder VJ, Madden MR, et al. Improved burn center survival of patients with toxic epidermal necrolysis managed without corticosteroids. *Ann Surg.* 1986;204:503-512.
22. Engelhardt SL, Schurr MJ, Helgeson RB. Toxic epidermal necrolysis: an analysis of referral patterns and steroid usage. *J Burn Care Rehabil.* 1997;18:520-524.